

**CASE REPORT**

Giant Retroperitoneal Liposarcoma

Navdeep Singh Saini, Rajeev Kapoor

Abstract

Liposarcoma, the most common type of retroperitoneal tumor, usually presents late with average weight of 15-20 kg, mostly in men. Surgery is considered to be gold standard even in giant retroperitoneal liposarcomas. We report a case of 65 year old man with a giant retroperitoneal liposarcoma and show that large tumor size is not necessarily a contraindication to surgical resection.

Key Words

Retroperitoneal Tumor, Sarcoma, Liposarcoma

Introduction

Retroperitoneal soft-tissue sarcomas are locally invasive tumors that remain occult for long periods and grow quite large due to abdominal cavity's remarkable ability to accommodate these slowly expanding masses with a paucity of attendant symptoms(1). The most frequent subtypes are liposarcoma (41%), leiomyosarcoma (28%), malignant fibrous histiocytoma (7%), fibrosarcoma (6%) and tumors of the peripheral nerve sheath(3%)(2). Liposarcomas are neoplasms of mesodermic origin derived from adipose tissue and correspond to 10-14% of all soft tissue sarcomas. They represent <1% of all malignant tumors(3,4). Retroperitoneal liposarcomas alone comprise 0.02-0.2% of all neoplasms (5). Approximately 85% of these are malignant (3). Because of usual late presentation, average diameter of the tumor is 20-25 cm with a weight of 15-20 kg (5). Their most typical manifestations are discomfort or non-specific abdominal pain and a palpable abdominal

mass. These tumors occur most frequently in men, usually in the fifth or sixth decade of life (6). Surgery is considered to be gold standard for treatment of liposarcoma. It requires aggressive approach including multiple resections or multi organ radical resection. Many a times, surgical resection is difficult, current chemotherapeutic agents are also not effective. Toxicity to other abdominal viscera is limiting factor for radiotherapy (2). There is low incidence of distal metastasis (7%) as compared to other histological subtypes that range from 15-34% (7). The objective of this study is to report a case of giant retroperitoneal liposarcoma.

Case Report

A 65 year old gentleman presented with a history of progressively increasing abdominal distension for last 7 years, severe respiratory discomfort with inability to lie supine for last 6 months. On examination, a hard mass that occupied the entire abdomen was palpated. There

From the Department of Surgery, CM C & Hospital, Brown Road, Ludhiana-141008 PB- India

Correspondence to : Dr. Navdeep Singh Saini, Assistant Professor, Department of Surgery, CM C & Hospital, Brown Road, Ludhiana-141008 PB- India

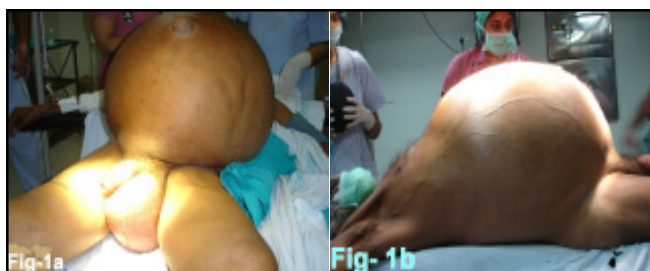


Fig 1-a,b- Pre-op pictures of the Patient with Huge Retroperited Mass

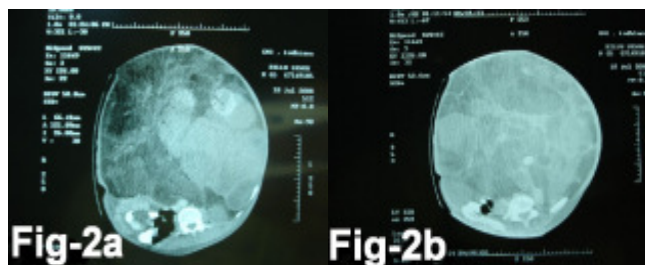


Fig2-a,b- CT Scan Showing Giant Lipomatours Mass Displaying Small Gut Towards Right Corner

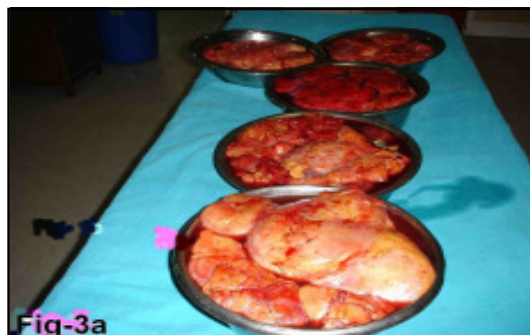

Fig -3a. Retroperitoneal Tumor Weighing 41kg

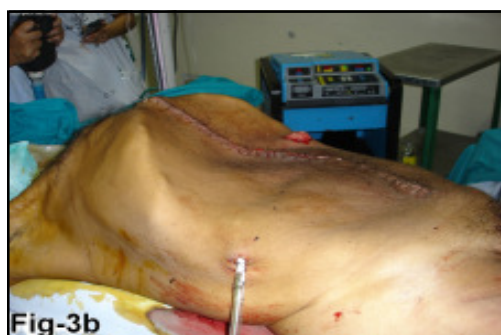

Fig3b. Post-op Picture Showing Emaciated

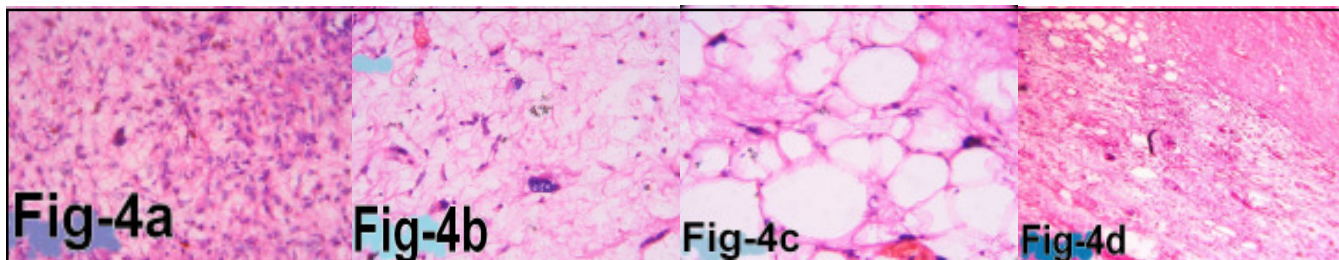


Fig-4a- Dedifferentiated Areas Showingphic Spindle Cells Along with few Multinucleated Tumor Giant Cell

Fig-4b- Lipoblasts with Bizarre Tumor Giant Cell. Fig-4c- Myxoid Areas With Plexiform Blood Vessels Fig-4d- Areas of Necrosis in the Tumor

was edema in both lower limbs and cachexia involving face and upper part of body (*Fig-1a,b*). Abdominal tomography revealed well defined heterogenous density mass with solid and fatty component, occupying the entire abdomen and pelvis, displacing the small gut posteriolaterally towards right side. Features suggestive of neovascularisation were present (*Fig-2 a,b*). At laparotomy, we noted a 54 X 43 X 38 cm³ mass of varied consistency (*Fig-3*), descending and sigmoid colon were adherent to it and displaced anteriolaterally. Left ureter was pushed across the midline towards right side. Whole of small gut was pushed towards right side. Descending and proximal sigmoid colon was also removed

with mass as they were badly stuck. Proximal descending colon was brought out as an end colostomy. No evidence of remnant disease was noticed at the time of stoma reversal. External beam radiotherapy was given post-operatively. Histopathological examination revealed liposarcoma of mixed type with dedifferentiated areas with a weight of 41 kg. Large bowel was free of tumor (*Fig-4*). Patient is alive and disease free at 15 months of evaluation.

Discussion

Retroperitoneal sarcomas, because of their deep seated location, are usually asymptomatic. Most common presentations are discomfort, non specific abdominal pain

or a palpable mass (6). Most common histological type is liposarcoma, corresponding to 41% of these tumors. It is slow growing and has a tendency to displace rather than invade adjacent structures. It is mostly seen in fifth or sixth decade of life and mostly seen in males (5,8). Around 20% of these tumors are >10cm at the time of diagnosis (2). Few cases of giant retroperitoneal liposarcomas have been reported.

Abdominal computed tomography and magnetic resonance imaging are most relevant tests to determine their size and relation to surrounding viscera (9). These tumors are malignant to start with, very rarely they can originate from benign lipomas. Their growth varies greatly from case to case and even in the same individual. Sometimes they remain silent for months or even years and sometimes grow rapidly. They are locally aggressive tumors, most commonly metastasizing in nearby major vessels and organs (8).

Complete surgical removal with tumor free margins is treatment of choice. Kidney, ureter and large bowel are most commonly resected if involved. The initial operation offers the best chance of cure. Giant tumor size should not be a contraindication to surgical resection. Radicality of surgical resection and not tumor size is associated with prognosis. Local failure occurs within 5 to 10 years after resection in up to 90 % of the cases(10). Factors related to local recurrence are inability to achieve free margins and limitations of adjuvant treatment (2,6). We have been able to find 3 published cases of retroperitoneal sarcoma larger than 30 kg, the mean weight of these tumors being between 15 and 20 kg. Present case may be considered amongst the largest reported for retroperitoneal liposarcoma.

Conclusion

In spite of their giant size, retroperitoneal liposarcomas should be approached with curative intent and aggressive attempt at complete surgical resection, which include liberal en bloc resection to achieve negative margins. Incomplete resection should be undertaken only for palliation of symptoms.

References

1. Storm KS, Mahvi DM. Diagnosis and management of Retroperitoneal soft tissue sarcoma. *Ann Surg* 1991 ;11: 214
2. Lewis JJ, Leung D, Woodruff JM, Brennan MF. Retroperitoneal soft-tissue sarcoma: analysis of 500 patients treated and followed at a single institution. *Ann Surg* 1998; 228: 355-65
3. Kilkenny JW, Bland KI, Copeland E M. Retroperitoneal Sarcoma. The University of Florida Experience. *J Am Coll Surg* 1996; 182: 329-39
4. Hassan I, Park SZ, Donohue JH, *et al.* Operative management of primary retroperitoneal sarcomas. A reappraisal of an institute experience. *Ann Surg* 2004; 239:244-50
5. Echenique-Elizondo M, Amodarain Arratibel JA. Liposarcoma retroperitoneal gigante. *Cir Esp* 2005, 77: 293-95
6. Morandeira A, Prieto J, Poves I, Cano JJS, Diaz C, Baeta E. Giant retroperitoneal sarcoma. *Can J Surg* 2008; 51: 79-80
7. McGrath PC, Neifeld, Lawrence W Jr, *et al.* Improved survival following complete excision of retroperitoneal sarcomas. *Ann Surg* 1984; 200: 200-04
8. Jaques DP, Coit DG, Hajdu SI, Bannan MF. Management of primary and recurrent soft-tissue sarcoma of the retroperitoneum. *Ann Surg* 1990; 212:51-59
9. Qiang FU. Huge retroperitoneal liposarcoma : a case report *Chinese Med J* 2007; 120 : 1117-18.
10. Gomez AH, Gutierrez co, Ortiz LK: Giant retroperitoneal Liposarcoma. *World J Surg Oncol* 2008; 6:115-18